



## Research Article

## HISTOLOGY OF THE DIGESTIVE TRACT OF THE ENDANGERED *SALMO OBTUSIROSTRIS* (TELEOSTEI: SALMONIDAE) FROM THE BUNA RIVER (NERETVA RIVER BASIN, BOSNIA AND HERZEGOVINA)

Wolf Stefan, I. and \*Markotić, I.

Department of Biology, Faculty of Science and Education, University of Mostar, Mostar, Bosnia and Herzegovina

Article History: Received 30<sup>th</sup> January 2024; Accepted 27<sup>th</sup> February 2024; Published 16<sup>th</sup> March 2024

### ABSTRACT

Morphological and histological studies are very useful for the characterization of the digestive tract, which provides important information for understanding the feeding habits and digestive physiology of fish. This paper presents the results of research of the histological structure of the digestive system of the endemic fish *Salmo obtusirostris* (Heckel, 1851) from the Buna River (Neretva River basin, Bosnia and Herzegovina). According to IUCN Red List, *S. obtusirostris* is considered Endangered B2ab (v) ver. 3.1, with decreasing population trend throughout its distribution area. A specimen (TL = 265 mm, SL = 245 mm, m = 251.52 g) of the species *S. obtusirostris* was caught in the Buna River in May 2019. As the basic material, digestive tract of the above-mentioned species was used, divided into esophagus, stomach, pyloric appendages, intestine, as well as the digestive glands, the liver and the pancreas. By using basic histological techniques, microscopic preparations were made from the tissues. When studying the microscopic structure of the organs of the digestive system of *S. obtusirostris*, it was established that the majority basically consists of mucosa (*tunica mucosa*), submucosa (*tunica submucosa*), muscular layer (*tunica muscularis*) and outer layer (*tunica serosa*). The histological structure of the digestive system of *S. obtusirostris* Heckel, 1851 is consistent with its diet.

**Keywords:** *Salmo obtusirostris*, Ecology, Histology, Buna river, Bosnia and Herzegovina.

### INTRODUCTION

*S. obtusirostris* (Heckel, 1851) is an endemic fish of the Adriatic drainage basin. It is distributed in the rivers of Krka, Jadro, Žrnovnica and Vrljika in Croatia, the Neretva River catchment area in Bosnia and Herzegovina and the rivers of Zeta and Morača in Montenegro. These populations were traditionally accepted as subspecies based on different morphological features (Mrakovcic & Mišetić, 1989). However, based on molecular diagnosis, these subspecies were recently declined (Snoj *et al.*, 2002) and probably some additional, both morphological and genetic, analysis should be conducted in the near future. The population from the Neretva River is genetically close to the Vrljika River population (Snoj *et al.*, 2008), but a recent additional morphometric report put it in closer relations with the River Zeta population (Duplić, 2014). According to IUCN Red List, *S. obtusirostris* is considered Endangered B2ab (v) ver. 3.1, with decreasing population

trend throughout its distribution area. The main threats are overfishing (sport fishing and household fishing for food, including poaching), hybridization with non-native trout, habitat destruction (dams) and water pollution (Crivelli, 2006; IUCN). As a rheophilic species, *S. obtusirostris* inhabits cold karst watercourses rich in oxygen, and prefers deeper and slower parts of watercourses. Aquatic invertebrates are dominant in the diet of *S. obtusirostris* (Čaleta *et al.*, 2015; Glamuzina *et al.*, 2018). The present work investigated the histology of the digestive system of *S. obtusirostris*. The histological description of the digestive system of *S. obtusirostris* is compared with other teleost fish, to know whether they conform to a standard pattern.

### MATERIAL AND METHODS

A specimen of the species *S. obtusirostris* (Figure1) was caught in the Buna River, near the mouth of the Buna River

\*Corresponding Author: Ivana Markotić, Ph.D., Assistant Professor, Department of Biology, Faculty of Science and Education, University of Mostar, Mostar, Bosnia and Herzegovina, Email: [ivana.markotic@fpmoz.sum.ba](mailto:ivana.markotic@fpmoz.sum.ba)

in the Neretva River N 43° 24' 09.9", E 17° 83' 47.3" in May 2019 (Figure 2).

### Laboratory Procedures

The taxonomic identification of the fish species was confirmed (Kottelat and Freyhof, 2007). The fish was dissected to expose the digestive tract, which was removed from the coelomic cavity. Tissue samples were fixed in 10% formalin for 24 hours. After fixation the digestive tract was submitted to microtomy to obtain fragments of the

digestive organs. The fragments were submitted to routine histological techniques, such as dehydration, clearing, infiltration and paraffin embedding (Figure 3). They were micro sectioned at 6  $\mu\text{m}$ . Samples were stained with Haematoxylin-eosin (HE) (Suvarna *et al.*, 2019).

### Microscopy

Histological study of the organs of the digestive system of *S. obtusirostris* species was performed with an Olympus BX 51 light microscope (Figure 4).



Figure 1. *Salmo obtusirostris* Heckel, 1851 (Photo: P. Barišić).



Figure 2. Sampling location – Buna River (Photo: P. Barišić).



Figure 3. Histokinette (Foto: I. W. Stefan) and fitter (Photo: D. Rumora).

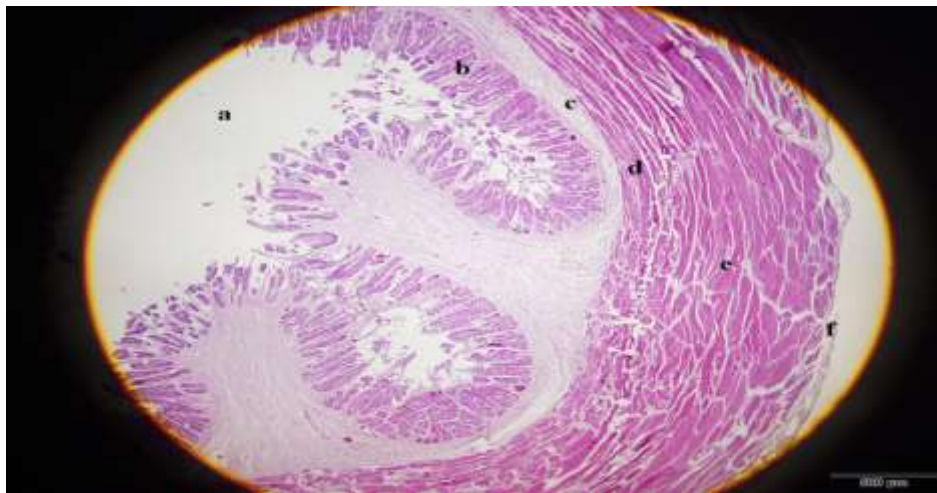


**Figure 4.** Light microscope Olympus BX 51 and microscopic preparations (Photo: D. Rumora).

## RESULTS

Total body length (265 mm), standard body length (245 mm) and the total weight of body (251, 52 g) of 1 fish were measured. Esophagus wall contains four distinctive layers: mucosa, submucosa, muscle layer and outer layer (figure 5). The mucosa forms high folds protruding deeply into the esophageal lumen. The mucosa (*tunica mucosa*) is constructed of *epithelium (lamina epithelialis)* and connective tissue (*lamina propria*), while the muscle layer of the mucosa (*lamina muscularis mucosa*) is not visible. The submucosa (*tunica submucosa*) is a layer of connective tissue permeated with numerous blood vessels and nerves

that separate the mucosa from the muscle layer. Esophageal glands and fatty tissue are an integral part of the esophageal submucosa. The muscle layer (*tunica muscularis*) consists of two layers of muscles: the inner (longitudinal) and the outer (circular) layer. The inner muscle layer (*stratum longitudinale*) is constructed of longitudinally placed muscle fibers that are separated from each other by loose tissue. The outer muscle layer (*stratum circulare*) is built of circularly arranged muscle fibers on which transverse stripes are clearly visible. This indicates the fact that the muscle layer of the esophagus of *S. obtusirostris* is made of skeletal muscle fibers.

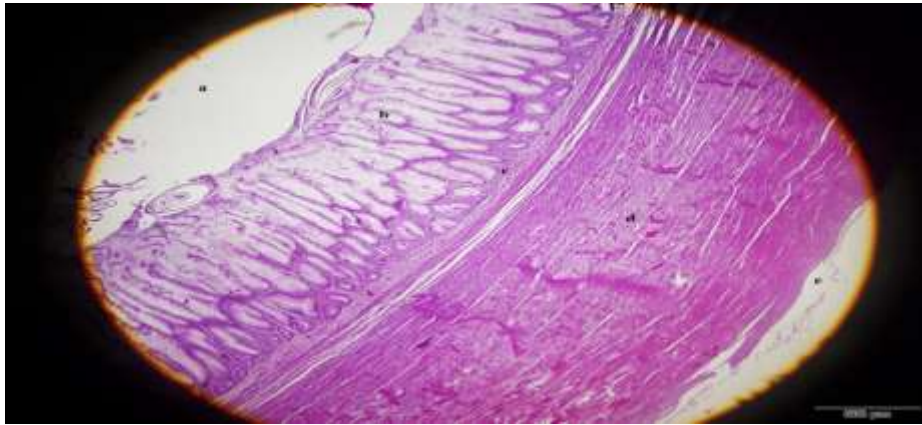


**Figure 5.** Transverse section through the esophagus of *Salmo obtusirostris*: a) lumen, b) *tunica mucosa*, c) *tunica submucosa*, d) *tunica muscularis*, e) *tunica muscularis*, f) *tunica adventitia* (HE, 40x).

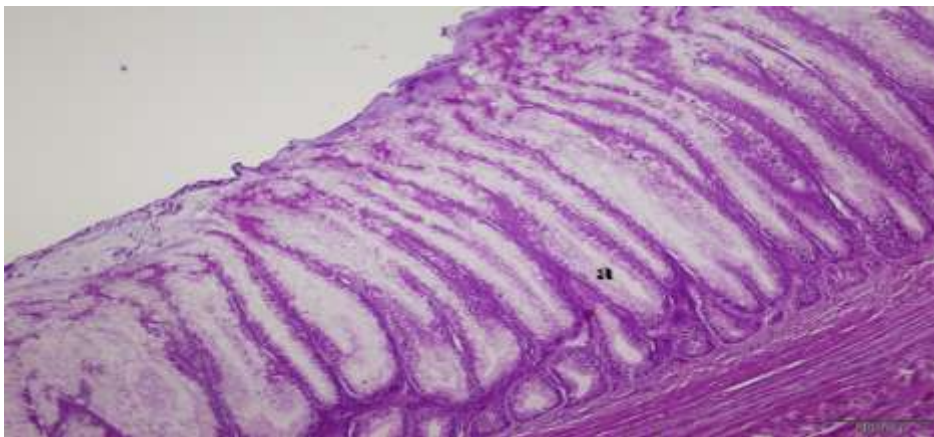
On a histological section through the stomach of *S. obtusirostris*, four layers can be noticed: mucosa, submucosa, muscle layer and outer layer (Figure 6). The mucosa does not form folds, and the *lamina propria* of the mucosa contains numerous gastric glands (Figure 7). The base of the gland is at the border with the submucosa, while the neck of the gland is located under the mucosal epithelium. Glandular cells in the base of the gland are built mainly of large extremely basophilic cells with a large

centrally located nucleus. In the neck of the gland, the glandular cells are round and bright and resemble mucous glands. The submucosa (*tunica submucosa*) of the stomach is made of loose connective tissue. The muscle layer (*tunica muscularis*) of the stomach is composed of two layers: the inner circular layer (*stratum circulare*) and the outer longitudinal layer (*stratum longitudinale*). The outer layer of the stomach (*tunica serosa*) is constructed of connective tissue.





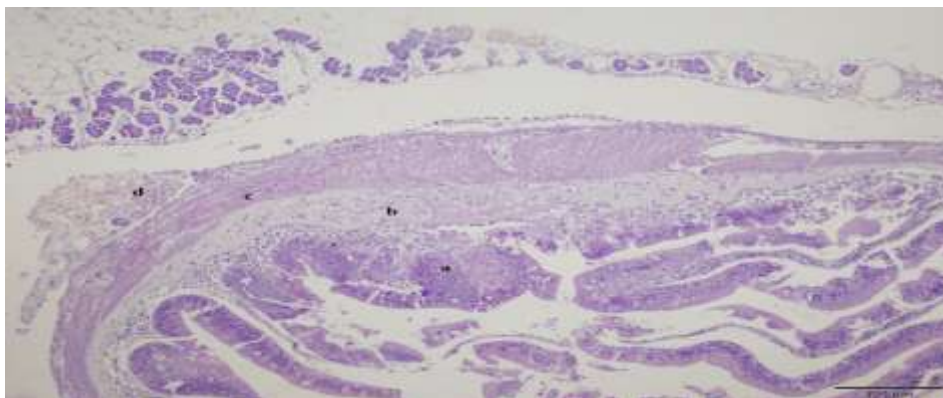
**Figure 6.** Transverse section through the stomach of the species *Salmo obtusirostris*: a) lumen, b) *tunica mucosa*, c) *tunica submucosa*, d) *tunica muscularis*, e) *tunica serosa* (HE, 40x).



**Figure 7.** Transverse section through the stomach of the species *Salmo obtusirostris*: a) gastric gland (HE, 100x).

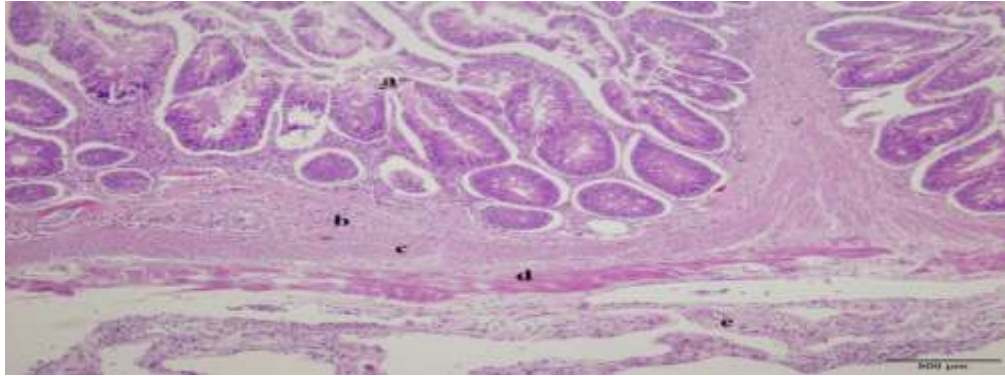
At the transition from the stomach to the intestine, pyloric appendages are noticed. On histological preparations, it can be seen that the wall of the pyloric appendage consists of a mucous membrane lined with cylindrical epithelium that carries microvilli on it. In places, between the epithelial cells, goblet cells are observed. The *lamina propria* is a

thin layer of connective tissue that separates the mucosa from the submucosa. The muscle layer of the pyloric appendages is made up of two muscle layers: inner circular and outer longitudinal. The wall of the pyloric appendages is lined externally by mesothelium (Figure 8).



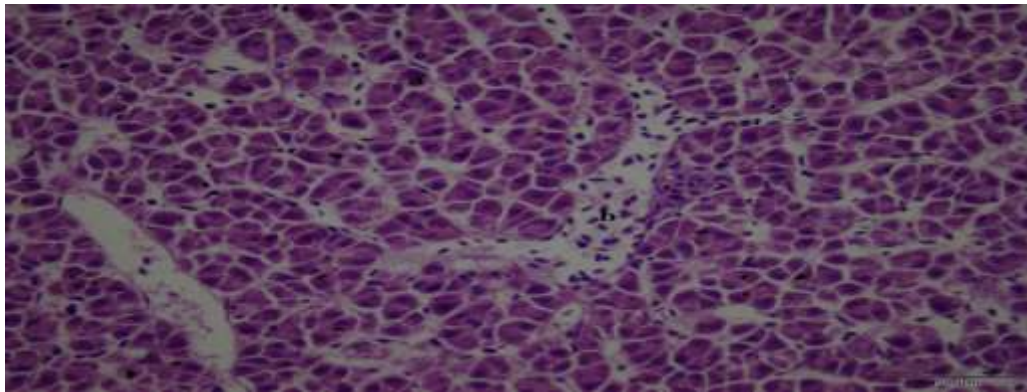
**Figure 8.** Transverse section through the pyloric appendage of the species *Salmo obtusirostris*: a) *tunica mucosa*, b) *tunica submucosa*, c) *tunica muscularis*, d) *tunica adventitia* (HE, 100x).

The wall of the front part of the intestine is very poorly preserved on histological sections, so it was not histologically analyzed for this reason. The wall of the back part of the intestine is built of mucosa, submucosa, muscle and outer layer (Figure 9). Regarding the muscle layer, the inner circular and outer longitudinal muscle layers are clearly visible.



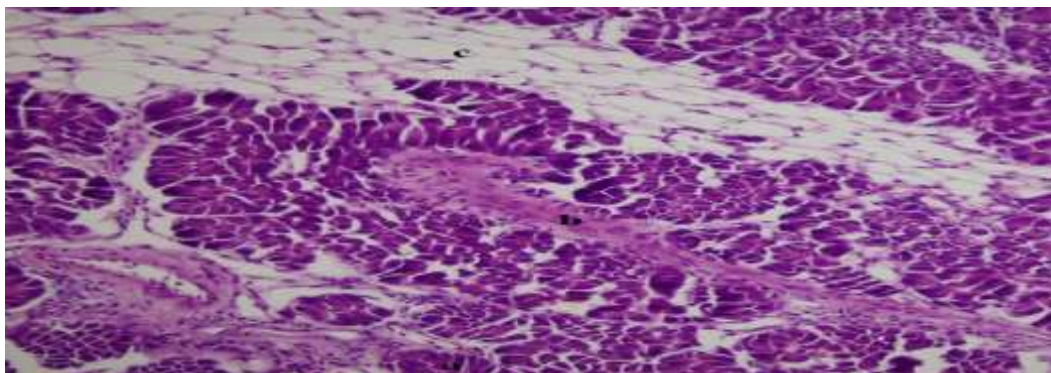
**Figure 9.** Transverse section through the wall of the final part of the intestine of the species *Salmo obtusirostris*: a) tunica mucosa, b) tunica submucosa, c) inner circular, d) outer longitudinal muscle layer, e) tunica serosa (HE, 100x).

The liver of *S. obtusirostris* is a complete organ that is histologically built of liver cells (hepatocytes). Hepatocytes are arranged in radial arrays around the central vein. Sinusoidal capillaries can be observed between rows of hepatocytes. Melano-macrophage center was not found on the histological preparations (Figure 10).



**Figure 10.** Histological structure of the liver of *Salmo obtusirostris* species: a) hepatocyte, b) blood vessel (HE, 400x).

The pancreatic tissue of the species *S. obtusirostris* can be noticed in the area between the pyloric appendages. The pancreas consists of numerous basophilic cells combined in serous acini. Fat tissue and blood vessels can be seen between the serous acini. On the histological sections through the pancreatic tissue, no structures were observed that could correspond to the sections through the islets of Langerhans (Figure 11).



**Figure 11.** Histological structure of the pancreas of the species *Salmo obtusirostris*: a) serous acini, b) blood vessel, c) fatty tissue (HE, 200x).

## DISCUSSION

Morphological and histological studies are very useful for the characterization of the digestive tract, which provides important information for understanding the feeding habits and digestive physiology of fish. The digestive system of fish is constructed of oropharyngeal cavity, esophagus, stomach, intestine and anal cavity. Digestive glands, liver and pancreas are also associated with the digestive system (Treer *et al.*, 1995). The oral cavity of fish is covered with a stratified epithelium. Salivary glands are missing in the oral cavity of fish, but they are replaced by goblet cells that secrete mucus (Bogut *et al.*, 2006). The digestive tract consisted of esophagus, stomach, and intestine that ends at the anus. The histological structure of the digestive tract of numerous fish species generally consists of mucosa, submucosa, muscularis, and serosa. Some differences of histological structures among fish digestive tracts are related to feeding habits, food, age, body shape, and weight (Mokhtar *et al.*, 2017). The digestive tract of carnivorous fish occupied a small part of the abdominal cavity and it consisted of esophagus, stomach, and intestine (Mokhtar *et al.*, 2017).

The digestive tract of *S. obtusirostris* species consisted of esophagus, stomach, pyloric appendages and intestine that ends at the anus. The esophagus in the study species is connected to the stomach. The wall of the esophagus is made of four different histological layers: mucosa, submucosa, muscle layer and outer layer. The mucosa (*tunica mucosa*) of the esophagus consists of epithelium (*lamina epithelialis*) and connective tissue (*lamina propria*), while the muscle layer of the mucosa (*lamina muscularis mucosa*) is not visible. The submucosa (*tunica submucosa*) is a layer of connective tissue permeated with numerous blood vessels and nerves that separates the mucosa from the muscle layer. Esophageal glands and fatty tissue make an integral part of the esophageal submucosa. The muscle layer (*tunica muscularis*) of the esophagus consists of two muscle layers: the inner (longitudinal) and the outer (circular) layer and is made of skeletal muscle fibers. The outer layer (*tunica adventitia*) of the esophagus is made of loose connective tissue. These results are compliant with the histological structure of the esophagus as reported by Mokhtar *et al.* (2017).

The shape of the stomach is different in individual fish species (Bogut *et al.*, 2006). Some fish from the genus *Gobio*, *Cyprinus* and *Rutilus* are stomachless (Al-Hussaini, 1949). In the fish species *S. obtusirostris* the stomach is layered by mucosa, submucosa, muscularis and outer layer. The mucosa does not fold, and the *lamina propria* of the mucosa contains numerous gastric glands. The base of the gland is at the border with the submucosa, while the neck of the gland is located under the mucosal epithelium. The gastric glands are the main part of the stomach mucosa in carnivorous and herbivorous fish (Al Abdulhadi, 2005). The submucosa (*tunica submucosa*) of the stomach is made of loose connective tissue. The muscle layer (*tunica muscularis*) of the stomach is composed of two layers: the inner circular layer (*stratum circulare*) and the outer longitudinal layer (*stratum longitudinale*). The outer layer

of the stomach (*tunica serosa*) is constructed of connective tissue.

In some fish with a stomach, pyloric appendages (*appendices pyloricae*) are located at the beginning of the intestine. The histological structure of the pyloric appendages is identical to the structure of the proximal part of the intestine. In the structural and functional sense, the pyloric appendages are an integral part of the foregut, and their role is to increase the contact surface of the digestive system, and thus a longer passage and better utilization of food. Pyloric appendages have a certain importance for the absorption of lipids and glucose (Bogut *et al.*, 2006). The wall of the pyloric process in the investigated species consists of a mucous membrane lined with cylindrical epithelium that carries microvilli. In places, between the epithelial cells, goblet cells can be noticed. The *lamina propria* is a thin layer of connective tissue that separates the mucosa from the submucosa. The muscle layer of the pyloric appendages consists of two muscle layers: inner circular and outer longitudinal layer. The wall of the pyloric appendages is lined externally by the mesothelium. The intestine of fish with a stomach has a similar structure to that of fish without a stomach. The wall of the intestine of fish consists of a mucous, muscle layer and serous layer. Morphologically, the intestine is not differentiated into separate parts, however, according to cytophysiological properties; there are differences (Bogut *et al.*, 2006). The intestine of fish is divided into three portions according to thickness of the wall, length of mucosal folds, and thickness of muscularis; anterior, middle (posterior), and rectum (Mokhtar *et al.*, 2017). A histological investigation of the structure of the wall of the end part of the intestine of the species *S. obtusirostris* has revealed that it consists of mucous membrane, submucosa, muscle layer and outer layer.

The liver is the highest glandular organ associated with the digestive system (Bogut *et al.*, 2006). The liver is a large digestive gland that is composed of parenchymal cells and lattice fibers. The fish hepatic parenchyma is not arranged into distinct lobules. Three patterns of organization of fish hepatic parenchyma are recognized. The first pattern is composed of hepatocytes, which are radially arranged around the central vein. The second arrangement called tubular pattern in form of tubules and the sinusoids form network around the tubules. The third arrangement is present in some fresh and marine teleosts, the hepatocytes lie in anastomosing lamina around the central vein (Mokhtar, 2017). The liver of *S. obtusirostris* is a complete organ that is histologically made up of liver cells (hepatocytes). Hepatocytes are arranged in radial arrays around the central vein. Sinusoidal capillaries can be observed between rows of hepatocytes. Fish pancreas tissue is structurally and functionally divided into endocrine and exocrine parts (Bogut *et al.*, 2006). Pancreatic tissue of the species *S. obtusirostris* can be noticed in the area between the pyloric appendages. The research confirmed that the pancreas consists of numerous basophilic cells united in serous acini. Between serous acini, fatty tissue and blood



vessels can be found. On the histological sections through the pancreatic tissue, no structures were observed that could correspond to the sections through the islets of Langerhans. The present study is the first record on *S. obtusirostris* digestive tract histology, suggesting that its histological features are mostly similar to those of other carnivorous fish and congruent to its feeding habits.

## CONCLUSIONS

The digestive system of the species *S. obtusirostris* Heckel, 1851 consists of the oral cavity, pharynx, esophagus, stomach, pyloric appendages, intestine and associated digestive glands, of liver and pancreas. When studying the microscopic structure of the organs of the digestive system of *S. obtusirostris*, it has been established that the majority basically consists of mucosa (*tunica mucosa*), submucosa (*tunica submucosa*), muscle layer (*tunica muscularis*) and outer layer (*tunica serosa*). The liver of *S. obtusirostris* consists of liver cells, hepatocytes, which are arranged in series of rays around the central vein. The pancreas of the species *S. obtusirostris* has an endocrine and an exocrine part. The exocrine part is made of basophilic cells that are united in serous acini, and the endocrine part of  $\alpha$  and  $\beta$  cells. The histological structure of the digestive system of *S. obtusirostris* Heckel, 1851 is consistent with its diet.

## ACKNOWLEDGMENT

The authors express sincere thanks to the Head of the Department of Biology, Faculty of Science and Education, University of Mostar, Mostar, Bosnia and Herzegovina, for the facilities provided to carry out this research work. I would also like to thank Associate Professor Jelena Tomac, M.D., PhD., Dijana Rumora bacc. med. lab. diagn. and Tina Rudančić bacc. med. lab. diagn. from the Institute of Histology and Embryology, Faculty of Medicine, University of Rijeka, Rijeka, Croatia, for their professional assistance.

## REFERENCES

- Al-Hussaini, A. H. (1949). On the functional morphology of the alimentary tract of some fish in relation to differences in their feeding habits; anatomy and histology. *Quarterly Journal of Microscopical Science*, 3-90, 109-139.
- Al Abdulhadi, H. A. (2005). Some comparative histological studies on alimentary tract of tilapia fish (*Tilapia spilurus*) and sea bream (*Mylio cuvieri*). *Egyptian Journal of Aquatic Research*, 31, 387-397.
- Bogut, I., Novoselić, D., Pavličević, J. (2006). Biologija riba I. Poljoprivredni fakultet u Osijeku, Osijek.
- Crivelli, A. J. (2006). *Salmo obtusirostris*. The IUCN Red List of Threatened Species 2006: e.T19862A9056634. <http://dx.doi.org/10.2305/IUCN.UK.2006.RLTS.T19862A9056634.en>. Downloaded on September 15, 2023.
- Čaleta, M., Buj, I., Mrakovčić, M., Mustafić, P., Zanella, D., Marčić, Z., Duplić, A., Mihinjač, T., Katavić, I. (2015). Hrvatske endemske ribe. Agencija za zaštitu okoliša, Zagreb.
- Duplić, A. (2014). Taksonomija i biološke značajke mekousne *Salmo obtusirostris* (Heckel, 1851) (Actinopterygii, Salmonidae). (Taxonomy and biological characteristics of softmouth trout *Salmo obtusirostris* (Heckel, 1851) (Actinopterygii, Salmonidae). PhD Thesis. University of Zagreb. (In Croatian).
- Glamuzina, B., Stanić-Koštroman, S., Matić-Skoko, S., Glamuzina, L., Muhamedagić, S., Rozić, I., Weiss, S., Pavličević, J. (2018). Recent status and life history traits of endangered soft-mouth trout, *Salmo obtusirostris* in the River Neretva catchment (Bosnia and Herzegovina) as a consequence of river alteration. *Journal of Applied Ichthyology*, 00, 1-9. <https://doi.org/10.1111/jai.13780>
- Mrakovčić, M., Mišetić, S. (1989). Status, distribution and conservation of the salmonid *Salmothymus obtusirostris* (Heckel) and the cyprinid *Aulopyge hugeli* (Heckel) in Yugoslavia. *Journal of Fish Biology*, 37A, 241-242. [https://doi.org/10.1016/0006-3207\(94\)00080-A](https://doi.org/10.1016/0006-3207(94)00080-A).
- Mokhtar, D. M. (2017). Fish histology: from cells to organs. Apple Academic Press, New Jersey.
- Kottelat, M., Freyhof, J. (2007). Handbook of European Freshwater Fishes. Publications Kottelat, Cornol.
- Snoj, A., Melkič, E., Sušnik, S., Muhamedagić, S., Dovč, P. (2002). DNA phylogeny supports revised classification of *Salmothymus obtusirostris*. *Biological Journal of the Linnean Society*, 77(3), 399-411. <https://doi.org/10.1046/j.1095-8312.2002.00130.x>
- Snoj, A., Bogut, I., Susnik, S. (2008). Evidence of genetically distinct population of Vrljika softmouth trout *Salmo obtusirostris* Heckel evolved by vicariance. *Journal of Fish Biology*, 72(8), 1945-1959. <https://doi.org/10.1111/j.1095-8649.2008.01816.x>
- Suvarna, S. K., Layton, C., Bancroft, J. D. (2019). Bancroft's theory and practice of histological techniques. 8<sup>th</sup> ed., Elsevier.
- Treer, T., Safner, R., Aničić, I., Lovrinov, M. (1995). Ribarstvo. Nakladni zavod Globus, Zagreb, 103-107.