



Research Article

HISTOMORPHOLOGICAL CHANGES OF SCENT GLANDS IN SOFT FURRED FIELD RAT, *MILLARDIA MELTADA*

S. Kalaiyarasan¹ and A. Amsath^{2*}

¹Department of Zoology, Government Arts College, Kumbakonam-612 001, Tamil Nadu, India

²Department of Zoology, Khadir Mohideen College, Adirampattinam-614 701, Tamil Nadu, India

Article History: Received 2nd April 2016; Revised 17th April 2016; Accepted 23rd April 2016

ABSTRACT

The histomorphological changes of four scent glands viz., preputial, flank, armpit and cheek glands were studied in soft furred field rat species of *Millardia meltada*. The size and weight of the glands measured to identify the variation among the glands of male and female rats. The histomorphological changes of the glands under the transmission electron microscopic study gives a clear picture about the secretory functions of the scent glands which gives variations among the scent glands. The morphological parameters of male and female glands were significantly varied each other. All the scent glands are modified sebaceous glands comprising of irregular shaped lobules or follicles or acini. The light microscopic analysis showed that the pair of preputial glands located on each side of the penis in male and clitoris in the female. Two pairs of flank glands were located on either side of the flank region; two pairs of armpit glands are present on each side of the armpit region and two pairs of cheek glands wise one pair on each side of the head between the ear and eye. The morphological parameters significantly varied from gland to gland of male and female. All the scent glands are modified sebaceous glands comprising of irregular shape lobules or follicles. The proportions of sebaceous and apocrine units differ among the glands. The secretory droplets accumulate in the cells and the debris pass along with the secretion through the ducts.

Keywords: Scent glands, histomorphology, Secretory functions, *Millardia meltada*.

INTRODUCTION

Rodents are considered one of the major pests of agricultural crops and stored food grains. Major crop losses caused by field rodents have been estimated in various places in India. Rodents may also adversely affect human health and cause great economic losses. Among rodents, rats are the dominant and highly infectious pests which infest human housing, sewers, animal shelters, day care facilities, warehouses, outdoor recreational areas etc. Furthermore, they serve as a reservoir of several important pathogenic vectors of diseases like plague, leptospirosis, rickettsial pox, rat bite fever, marine typhus fever, and so on (Jackson 1987). These detrimental effects are more pronounced particularly in developing countries like India. Thus, efforts have been made to control rats in some of the large metropolitan areas by using chemical rodenticides over the past few years. However, chemical control methods are made less effective by the rodent's bait shyness.

Chemical identities of mammalian urinary cues in the mouse, tiger, elephant and bovine (Kumar *et al.*, 2000) are available. Furthermore, chemical characterization and the

biological significance of secretions of the preputial gland (Kannan *et al.* 1998) and clitoral gland (Kannan and Archunan 2001) of laboratory rats and the cheek gland of the lesser bandicoot rat (Kannan and Archunan 1999) have recently been reported. However, chemical compounds of this type in rat urine have not yet been characterized. Therefore, the present study was undertaken to characterize at urinary compounds, to investigate the bioactivity of the identified compounds, and to analyze the biological significance of the identified compounds with a view to producing a pheromone trap to contribute to rodent pest management programs.

The ability for social and solitary animals to recognize individuals is important in the maintenance of stable social groups, parent-offspring dynamics, inbreeding avoidance, and the regulation of competitive relationships (Tibbetts and Dale 2007). As an important mode of communication in mammals, chemical signals play a vital role in individual discrimination/ recognition systems. Mammal's chemical signals can send powerful messages with behavior modulating effects that may be of considerable social importance. The major difference between pheromones and

*Corresponding author: Dr. A. Amsath, Associate Professor, Department of Zoology, Khadir Mohideen College, Adirampattinam-614 701, Tamil Nadu, India, Email: aamsath@gmail.com, Mobile: +91 9524582977.

other chemical signals is in the output: when processed by the brain. Chemical signals result in the sensation of smell, whereas pheromone signals trigger a unique characteristic behavioral or physiological response (Ben Ari, 1998). Mammalian pheromones are found to be involved in sexual attraction (Kannan *et al.*, 1998). The scent of glandular secretions (apocrine, sebaceous, and eccrine gland secretions) and excretions (urine and feces) provide cues related to individual identity, reproductive state, age, gender, and social rank and may elicit specific behaviors and physiological responses in receivers (Lai *et al.* 1996).

The secretions of scent glands have a distinct function in rodent behavior. Among the scent glands present in rodents, the preputial glands of the rat play an important role in the production of olfactory substances which attract the opposite sex (Kannan *et al.*, 1998). Specialized cutaneous glands which produce odoriferous secretions are found in a number of mammals (Mykutowycz, 1970). Usually, the scent producing glands occur in discrete patches or association in the skin at a number of locations in the body (Kumari, 1982). The secretion of such glands has been attributed a number of functions pertaining to olfactory communication among rodents (Thiessen and Yahr, 1977). The Indian gerbil, *Tatera indica* and the soft furred field rat, *Rattus meltada pallidior* is being reported for the first time in the genus *Tatera* and in any of the *Rattus* found on the Indian sub-continent. This paper is concerned primarily with the differences of ultra structure variations of four scent glands viz., preputial, flank, armpit and cheek glands the soft furred field rat, *Millardia meltada* and the critical analysis of morphological parameters among the glands of male and female rats.

MATERIAL AND METHODS

Adult soft-furred field-rats were collected from Kumbakonam area, Thanjavur District, Tamil Nadu, India. Freshly captured rats were sacrificed by cervical dislocation under mild dose of diethyl ether anesthesia. Fixation by vascular perfusion was generally carried out intracardially which intum offered a good preservation of scent glands such as Preputial, flank, cheek and armpit glands excised and used for histomorphological studies. The selected glandular tissues were fixed in Bouin-Hollande fluid, embedded in paraffin and sectioned serially (longitudinal or cross) at 6-8 μ m thickness. The sectioned materials were stained with Ehrlich's Haematoxylin and Eosin and mounted using DPX. Stained sections were examined under a compound binocular microscope fitted with a photomicrographic attachment.

RESULT AND DISCUSSION

Histomorphological studies

The size and weights of the glands were significantly varied among the glands of female. The light microscopic structure of scent glands were studied for male glands of preputial, flank, armpit and cheek glands and for female

glands of clitoral, flank, armpit and cheek glands of *M. meltada* and their secretions details are given in the Figure 1, which gives a clear picture about the secretory functions of the scent glands. All the scent glands are modified sebaceous glands comprising of irregular shaped lobules or follicles. The proportions of sebaceous and apocrine units differ from gland to gland. The secretory droplets accumulate in the cells until they become engorged and die and the debris pass along with the secretion through the ducts.

Microscopic observations

The studies in the microscopy illustrations of figures 2 and 3 showing the variations in the histomorphological structures of four sent glands such as; preputial, flank, armpit and cheek glands in male rat and armpit, cheek, flank and clitoral glands in female rat of soft furred field rat species of *M. meltada*. The size and weights of the glands were measured to reveal any variation among the glands irrespective of sex. The histomorphological study gives a clear picture about the secretory functions of the scent glands.

A pair of preputial glands are located, one on each side of the penis in male and clitoris in the female of rat. Two pairs of flank glands are located one pair on either side of the flank region. Two pairs of armpit glands present on each of the armpit region. Two pairs of cheek glands are located on each side of the head between the ear and eye. The morphological parameters significantly varied from gland to gland and male to female. All the scent glands are modified sebaceous glands comprising of irregular shaped lobules or follicles. The proportions of sebaceous and apocrine units differ from gland to gland. The secretory droplets accumulate in the cells until they become engorged and die and the debris pass along with the secretion through the ducts.

Histological nature of the scent glands in male rat

Result of the studies showing in the figure-2 that the preputial gland of male rat with distinguished nucleus (N), the secretory cell has large nucleus and having with high nuclear cytoplasmic ratio. The nucleus of the preputial gland produced large dense with rich amount of heterochromatin. The mature secretory cells released the secretory contents in to the lumen and such cells look like empty cells. The cheek gland of male rat consists of more amounts of granulated substances which are scent sources of rat. The nucleus of the cheek gland has less amount of heterochromatin which produces less dense granular substance. The armpit gland consists of distinguished flask shaped cells with numerous connective and desmosomes. The cytoplasm of the armpit gland cells consists of more amounts of lipid vacuoles and mixed minute granulated substances. The flank gland of male rat cytoplasm contained dense particles with lipid vesicle. The flank gland cytoplasm consists of a unique structure in the cytosolic solution.

Histological nature of the scent glands in female rat

Result of the studies in female rat showing in the figure-3 the clitoral gland of female rat shows the distinguished nucleus and the significance of this cell is the presence of small nucleus with high nuclear cytoplasmic ratio and it shows the occurrence of large vacuole with rich amount of reticular system. The cheek gland of female rat has distinguished nucleus and the significance of the female scent gland is the presence of large vesicle with an elongated nucleus having more number of mitochondria. The cheek gland consists of large dense nucleus with rich amount of heterochromatin. The mature secretory cells released all the secretory contents into the lumen which cells look like empty cells. The armpit gland of female rat consists of distinguished nucleus with high nuclear cytoplasmic ratio and has an endoplasmic reticulum. The armpit gland has of large euchromatin nucleus with rich amount of membrane wrinkles. The flank gland of female rat consists of distinguished flask shaped nucleus and margin is endorsed by the occurrence of heterochromatin. The flank gland cell has large vacuoles with high nuclear cytoplasmic ratio.

Some of the species like, *Meriones hurrianae* (Kumari *et al.*, 1981) and *M. unguiculatus* (Thiessen and Yahr, 1977) studied that the ventral scent marking gland is present in both sexes whereas in *Rattus meltda pallidior* present only in male rat. In another category, it is present in males but also in a very low proportion of females like *Tatera indica*. In *M. hurrianae*, the gland is present in 100 per cent males and females but in male rat of *T. indica* and *R. m. pallidior*, it is present only in 91 and 74 percent respectively. The absence of the ventral marking gland from one sex, usually the female, and from a certain proportion even in the males is rather perplexing. It is

expected that a gland which has developed during the evolutionary process should have a definitive function.

A comparison of the gland size in the three species in which it occurs among the desert rodents reveals that it is largest in male *R. m. pallidior*, smallest in *T. indica* and that of *M. hurrianae* assumes a middle position. It is imperative to visualize that the size of the gland should be related to the magnitude of its function. The ventral scent marking gland among rodents has been attributed a number of functions: territorial (Mykutowycz, 1962; Thiessen, 1968); familiarization, denoting the home (Daly, 1977); reproduction (Mitchell, 1967); advertising ready-to-mate stage in females (Kumari and Prakash, 1981a and b); and social hierarchy (Kumari and Prakash, 1981c) and so on. If the function of the gland was only to scent mark its home range with its sebum exudation, indicating territoriality; the area of home range of a rodent should be proportional with the area of the gland since the requirement of sebum will be more in a species which has a larger home range.

In the study, the growth of the scent marking gland in *M. meltda* is a continuous process, it keeps on growing throughout the life time of the rodents but exhibit sporadically a significantly high growth rate at certain age. The correlation between the body weight (in a way indicating age) and the gland measurements also confirm the observations about the process of its continuous growth. The females *M. meltda* show interest in the scent marks of the males (Idris and Prakash, 1981; Prakash and Idris, 1982). A number of ethological investigations are in progress to understand the role of scent marking among desert rodents in chemical communication (Kumari and Prakash, 1981a, b, c; Prakash and Idris, 1982), and more exhaustive work may unveil the mystery of the role of this specialized odour producing gland present in a few rodents only.

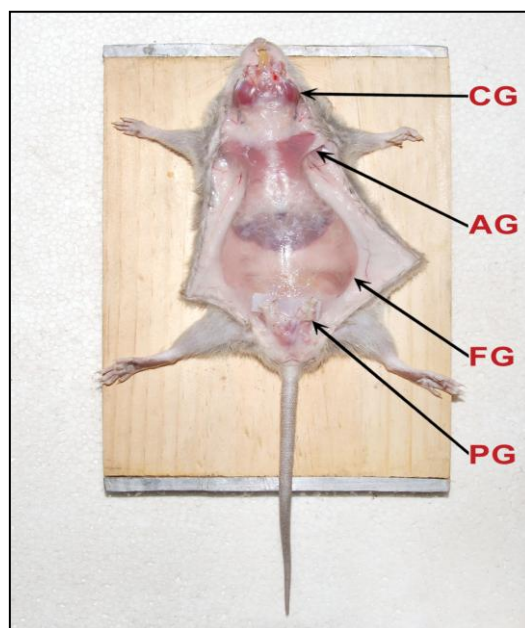


Figure 1. Histomorphological structures of male rat showing armpit (A), cheek (B), flank (C), and preputial (D) glands in male rat.

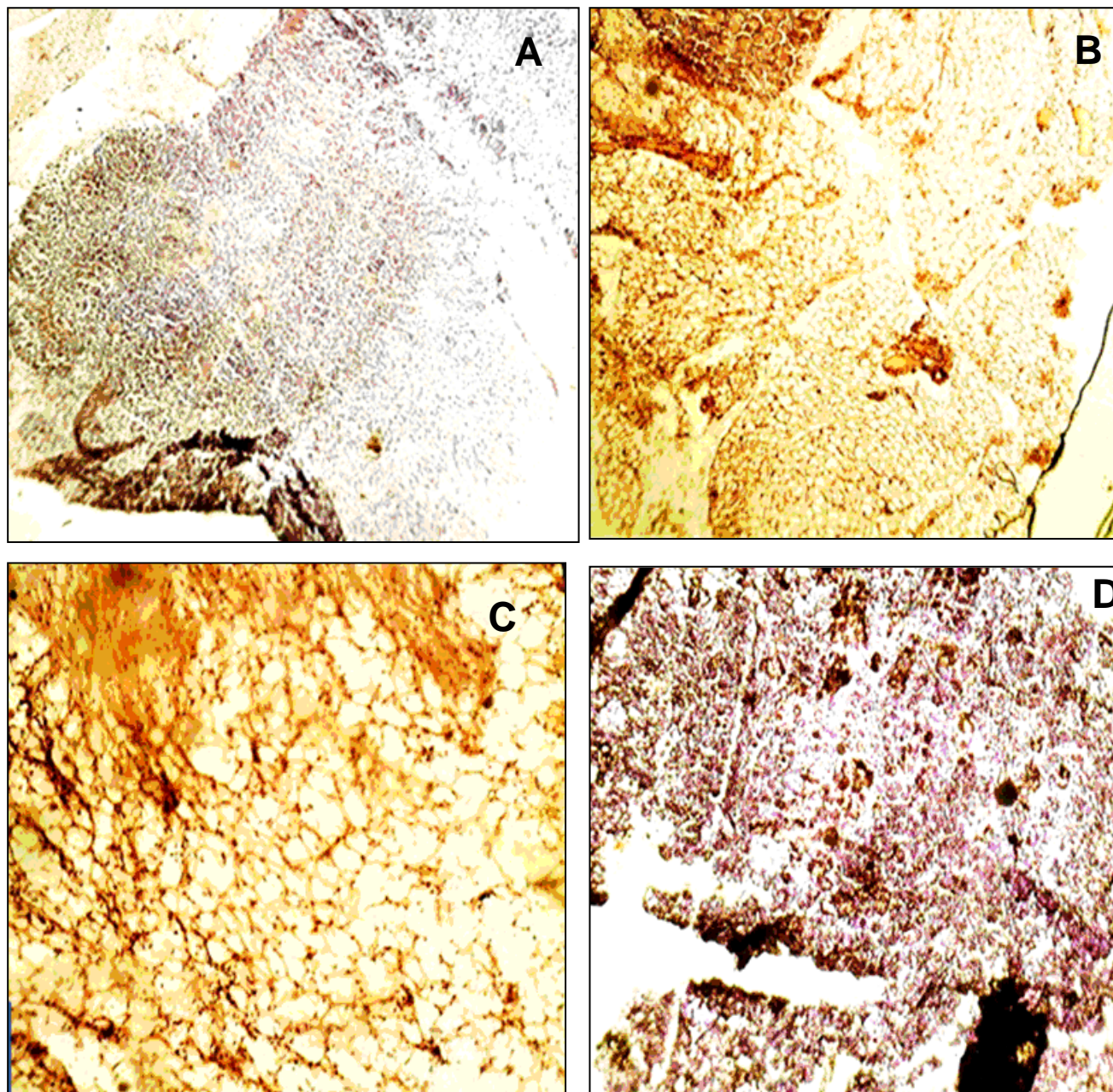


Figure 2. Histological nature of scent glands: A-Armpit, B-Cheek, C-Flank and D-Preputial glands in male rat showing by electron microscopic illustration.

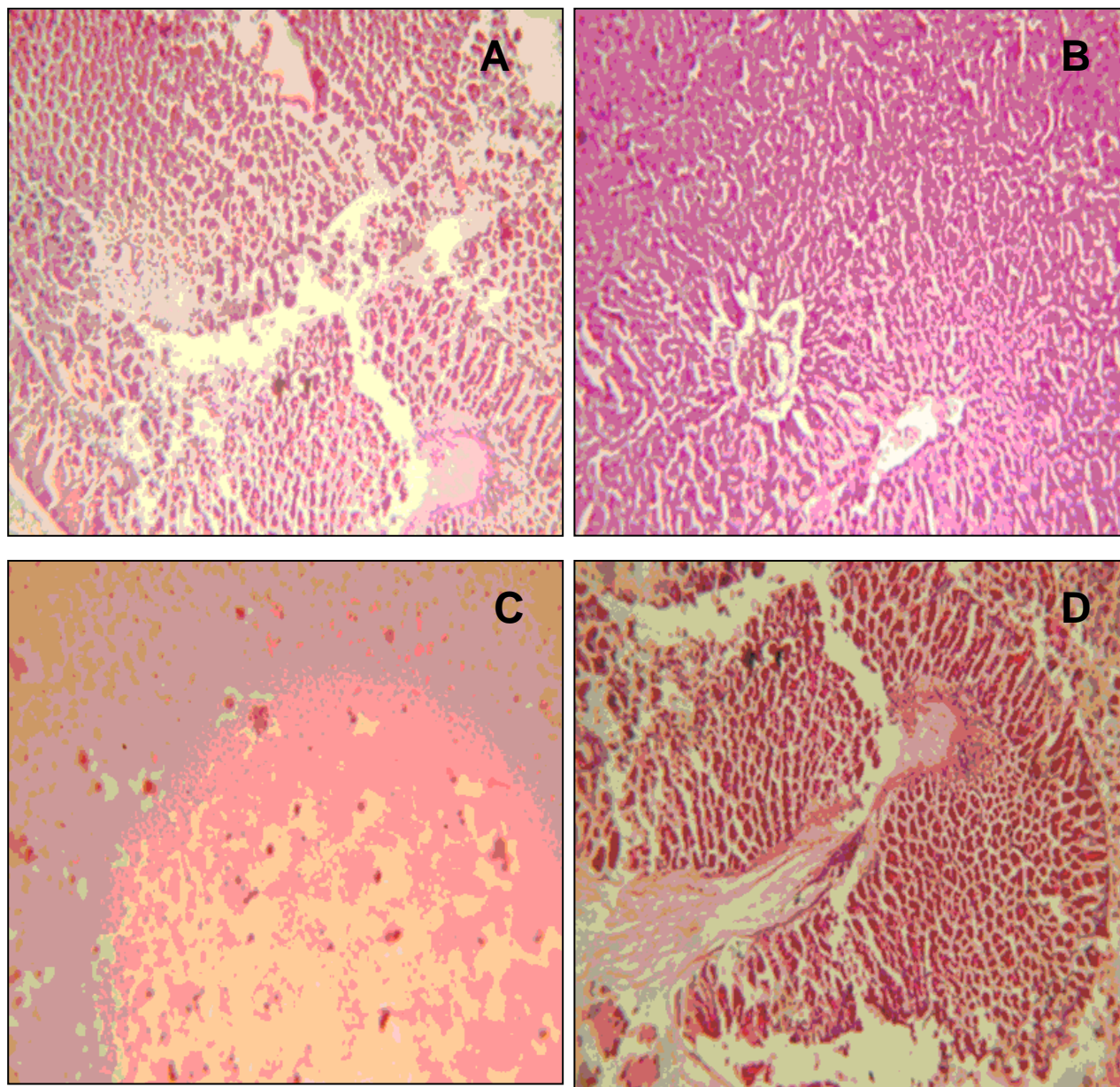


Figure 3. Histological nature of scent glands: A-Armpit, B-Cheek, C-Flank and D-Clitoral glands in female rat showing by electron microscopical illustrations.

CONCLUSION

The ultra structural and the microscopic studies of the different scent glands of male and female rat of *M. melstada species* reveals that the presences of more secretions which are released for territorial, familiarization, scent mark its home range with sebum exudation and reproduction activities. It may be used to control the rodent in the field.

ACKNOWLEDGEMENTS

The authors are thankful to the UGC for the award of Rajiv Gandhi National Fellowship for this work and also to the Principal and Head of the Department of Zoology, Government Arts College (Autonomous), Kumbakonam for the facilities provided to carry out this work.

REFERENCES

- Ben-Ari, E. T., 1998. Pheromones: What's in a name? *Bioscience*, 48, 505-511.
- Daly, M., 1977. Some experimental tests of the functional significance of scent-marking by gerbils (*Meriones unguiculatus*). *J. Comp. Physiol. Psychol.*, 91, 1082-1094.
- Idris, M. and Prakash, I., 1981. Behavioural responses of the Indian gerbil *Tatera indica* to conspecific sebum odour of the ventral scent marking gland. *Proc. Indian. Acad. Sci.*, 91, 259-265.
- Jackson WB. 1987. Current management studies for commensal rodents. In HH Genoways, ed. Current

- mammalogy, Vol. 1. New York: Plenum Publishing. pp. 495-512.
- Kannan, S. and Archunan, G., 1999. Identification of volatile compounds from cheek glands of lesser bandicoot rats and assessment of behavioural responses for identified compounds. *Indian J. Exp. Biol.*, 37, 798-802.
- Kannan, S. and Archunan, G., 2001. Chemistry of clitoral gland secretion of the laboratory rat: Assessment of behavioural response to identified compounds. *J. Biosci.*, 26, 247-252.
- Kannan, S., Ramesh Kumar, K. and Archunan, G., 1998. Sex attractants in male preputial gland: Chemical identification and their role in reproductive behaviour of rats; *Curr. Sci.*, 74, 689-691.
- Kumar, K.R., Archunan, G., Jeyaraman, R. and Narashimhan, S., 2000. Chemical characterization of bovine urine with special reference to oestrus. *Vet. Res. Commun.* 24, 445-454.
- Kumari, S. and Prakash, I., 1988. Relative efficacy of male and female conspecific urine in masking shyness behaviour in Indian gerbil, *Tatera indica*. *Indian Acad. Sci. (Anim. Sci.)*, 93, 431-436.
- Kumari, S., 1982. The structure functional significance of the ventral scent marking gland in three rodent species. Ph. D. Thesis, p. 1-197.
- Kumari, S. and Prakash, I., 1981a. Behavioural responses of *Meriones hurrianae* (Jerdon) to conspecific sebum odour of ventral sebaceous gland. *Biol. Behav.*, 6, 255-263.
- Kumari, S. and Prakash, I., 1981b. Scent marking behaviour of *Meriones hurrianae* during oestrus. *Anim. Behav.*, 29, 1269-1271.
- Kumari, S. and Prakash, I., 1981c. Observations on the social behaviour of the Indian desert gerbil, *Meriones hurrianae*. *Proc. Indian. Acad. Sci.*, 90, 463-471.
- Kumari, S., Cowan, P., and Prakash, I., 1981. The mid-ventral gland of the Indian desert gerbil, *Meriones hurrianae* (Jerdon). *Acta Theriol.*, 26, 97-106.
- Lai, S-C., Vasilieva, N.Y., Johnston, R.E., 1996. Odors providing sexual information in Djungarian hamsters: evidence for an across-odor code. *Horm Behav.* 30, 26-36.
- Mitchell, O.G., 1967. The supposed role of the gerbil ventral gland in reproduction. *J. Mammal.*, 48, 142.
- Mykytowycz, R., 1970. The role of skin glands in mammalian communication. In: *Advances in Chemoreception*, Eds. Johnston, J.W., Moulton, D.G. and Turk, A. *Appleton Century Crofts*, p. 327-360.
- Prakash, I. and Idris, M., 1982. Responses to conspecific odour of the scent marking gland by *Rattus meltda*. *Angew. Zool. Bd.*, 69, 481-486.
- Thiessen, D.D., 1968. The root of territorial marking in the Mongolian gerbil: A problem of species common topography. *Behav. Res. Meth. Instru.*, 1, 70-76.
- Thiessen, D.D. and Yahr, P., 1977. *The Gerbil in Behavioural Investigations*. University of Texas Press, p. 1-202.
- Tibbetts, E.A. and Dale, J., 2007. Individual recognition: it is good to be different. *Trends Ecol. Evol.*, 22, 529-537.